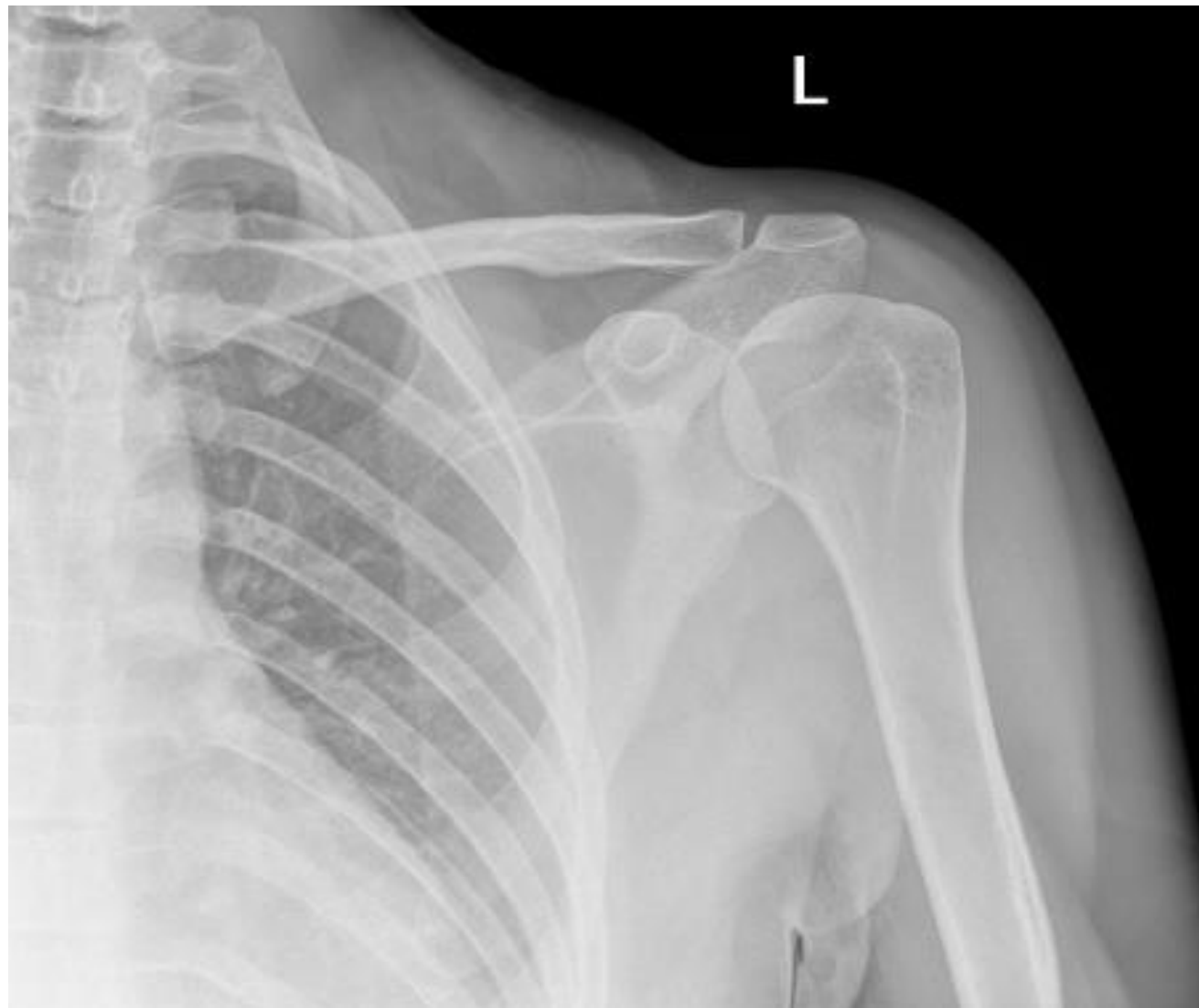
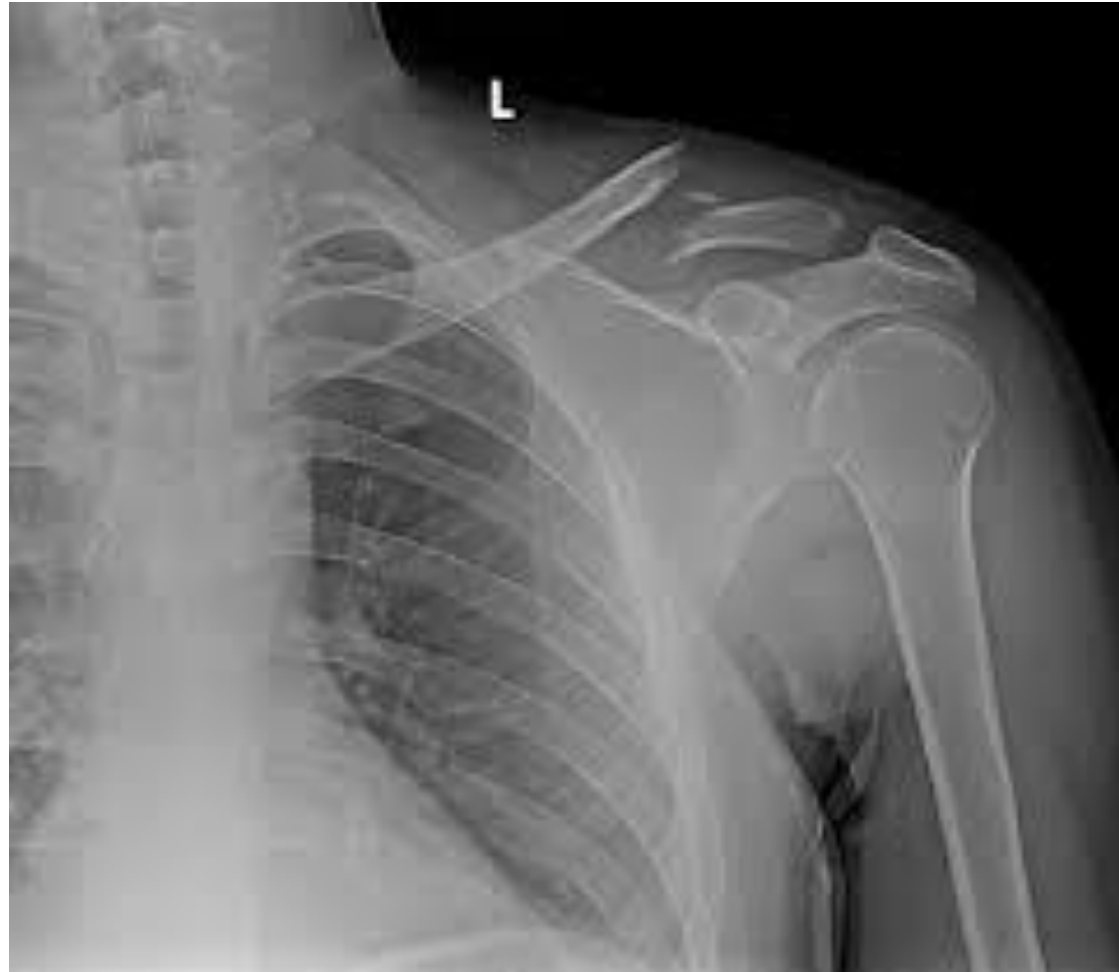

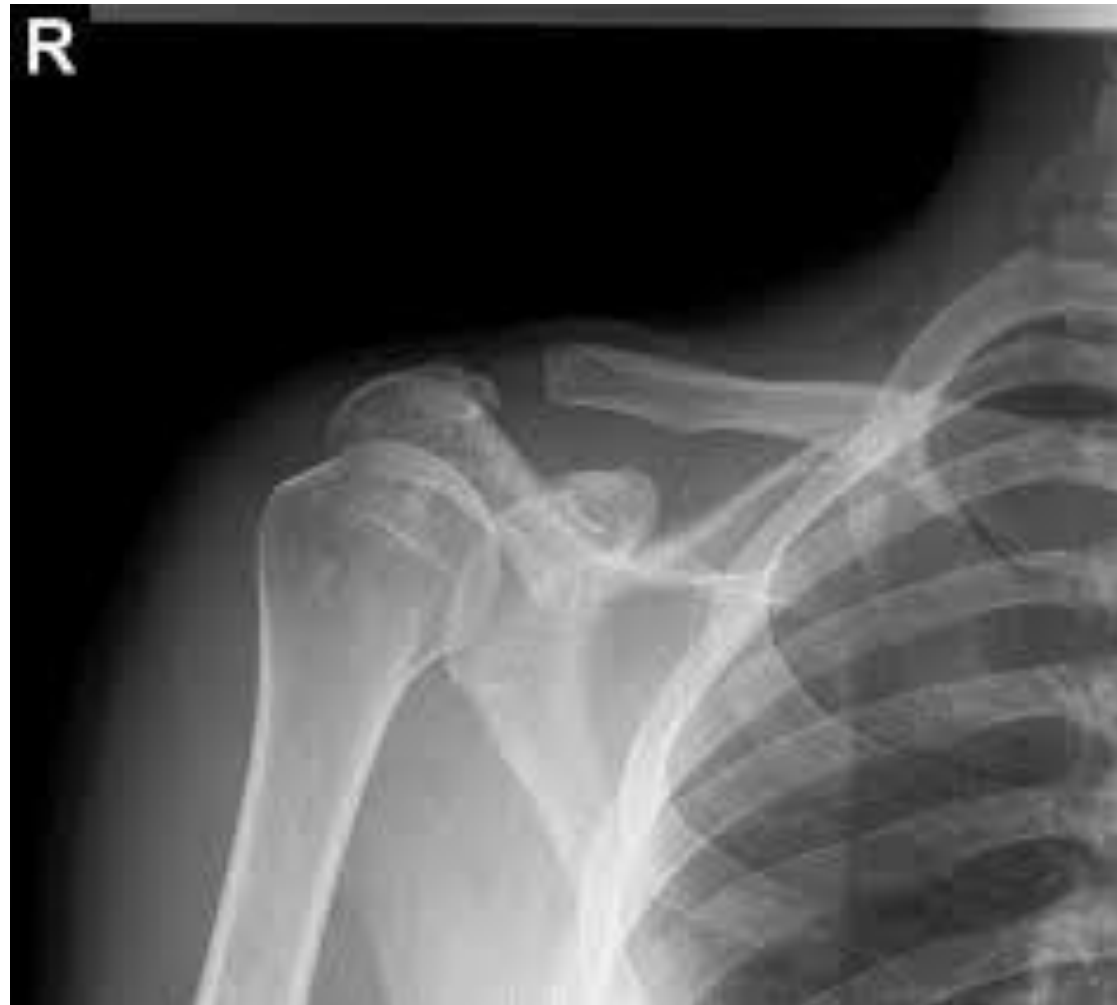# Normal Adult Shoulder



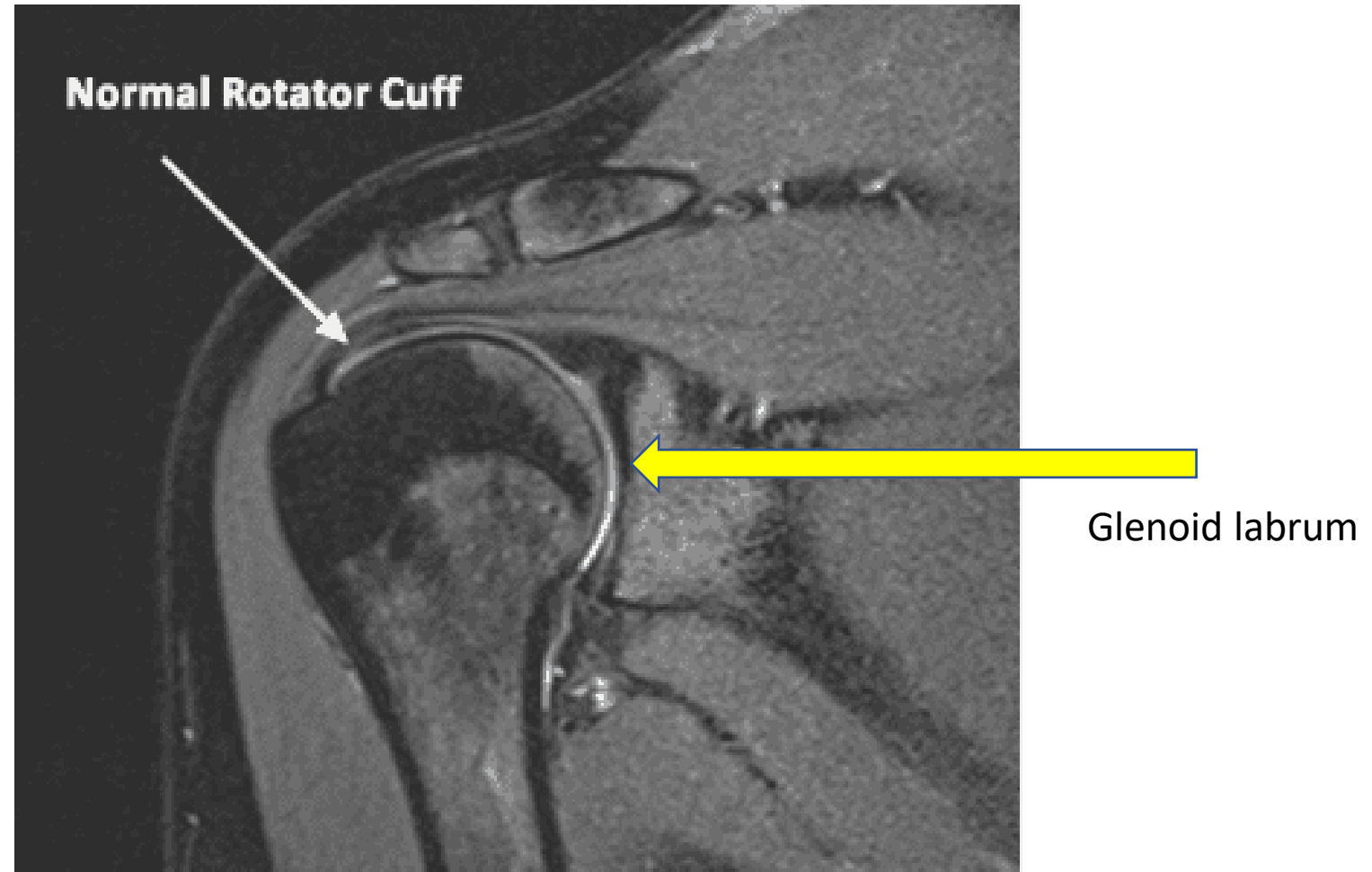
# Broken Clavicle



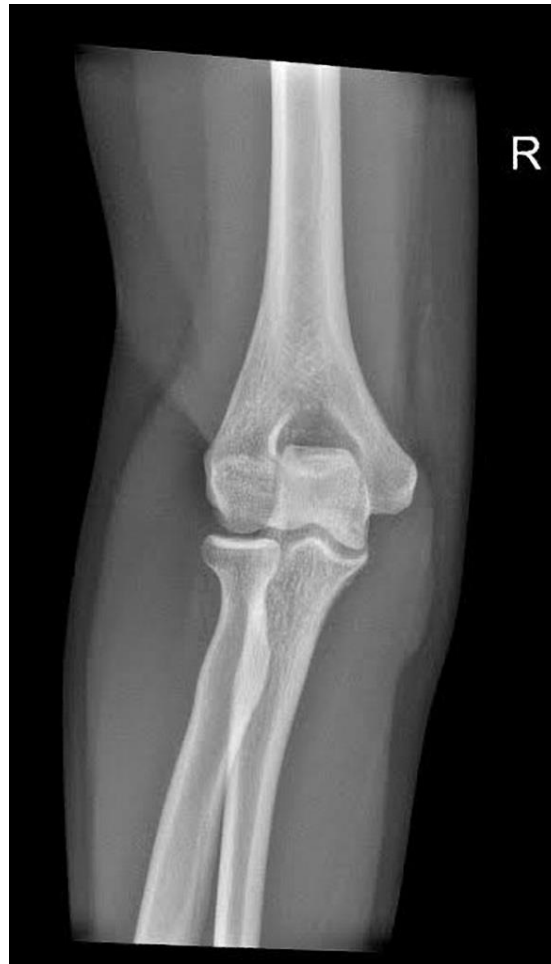# Separated Shoulder



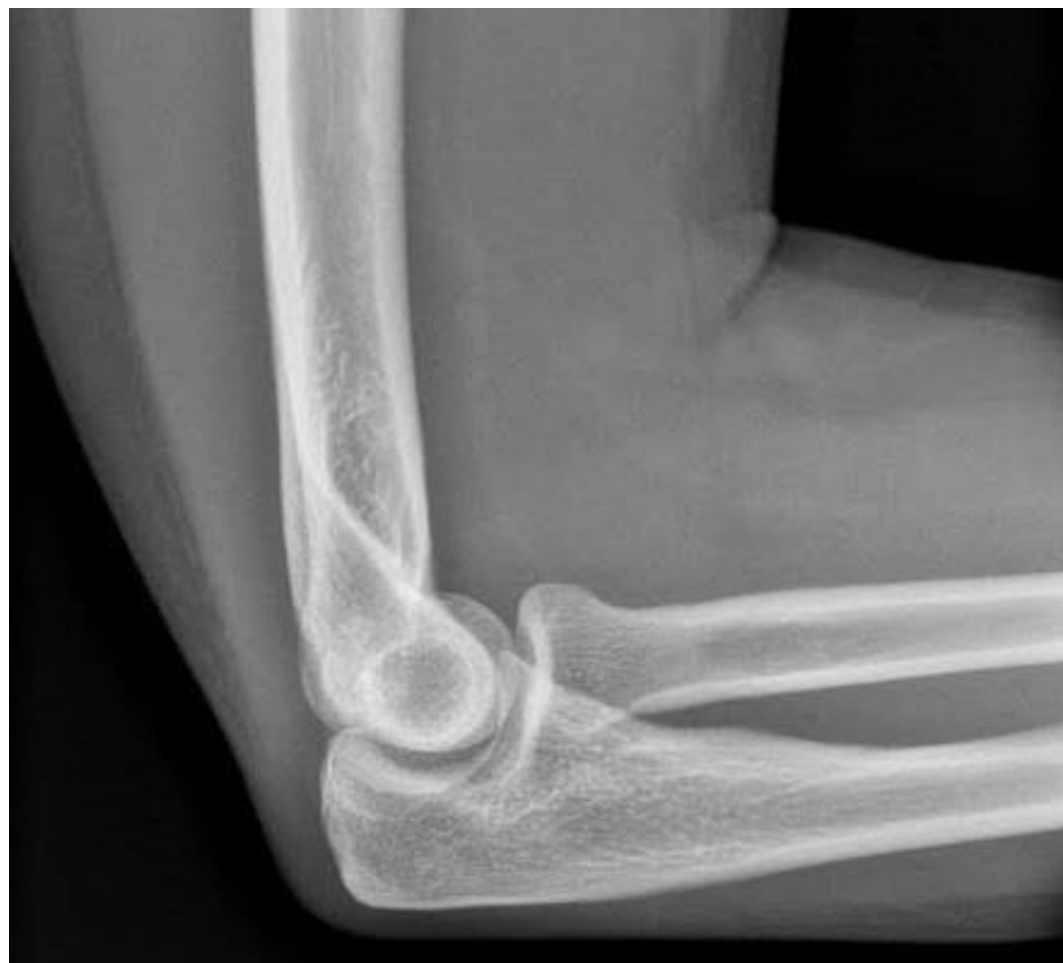# MRI of Shoulder



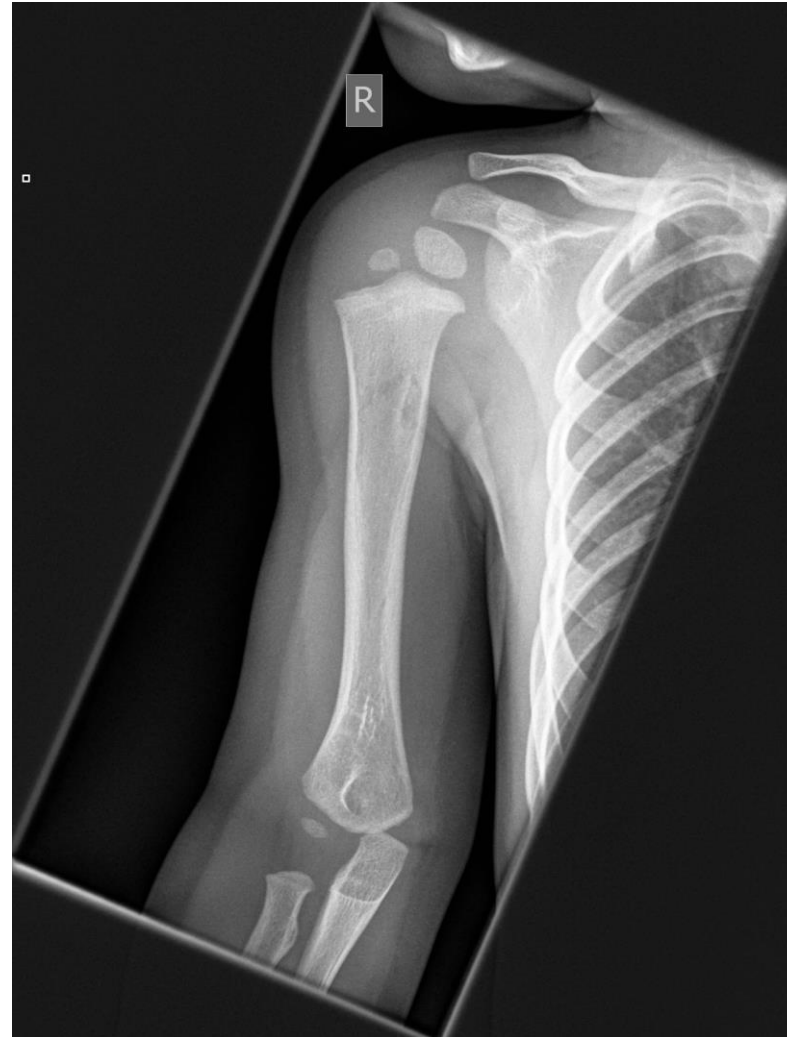# Normal Adult Elbow



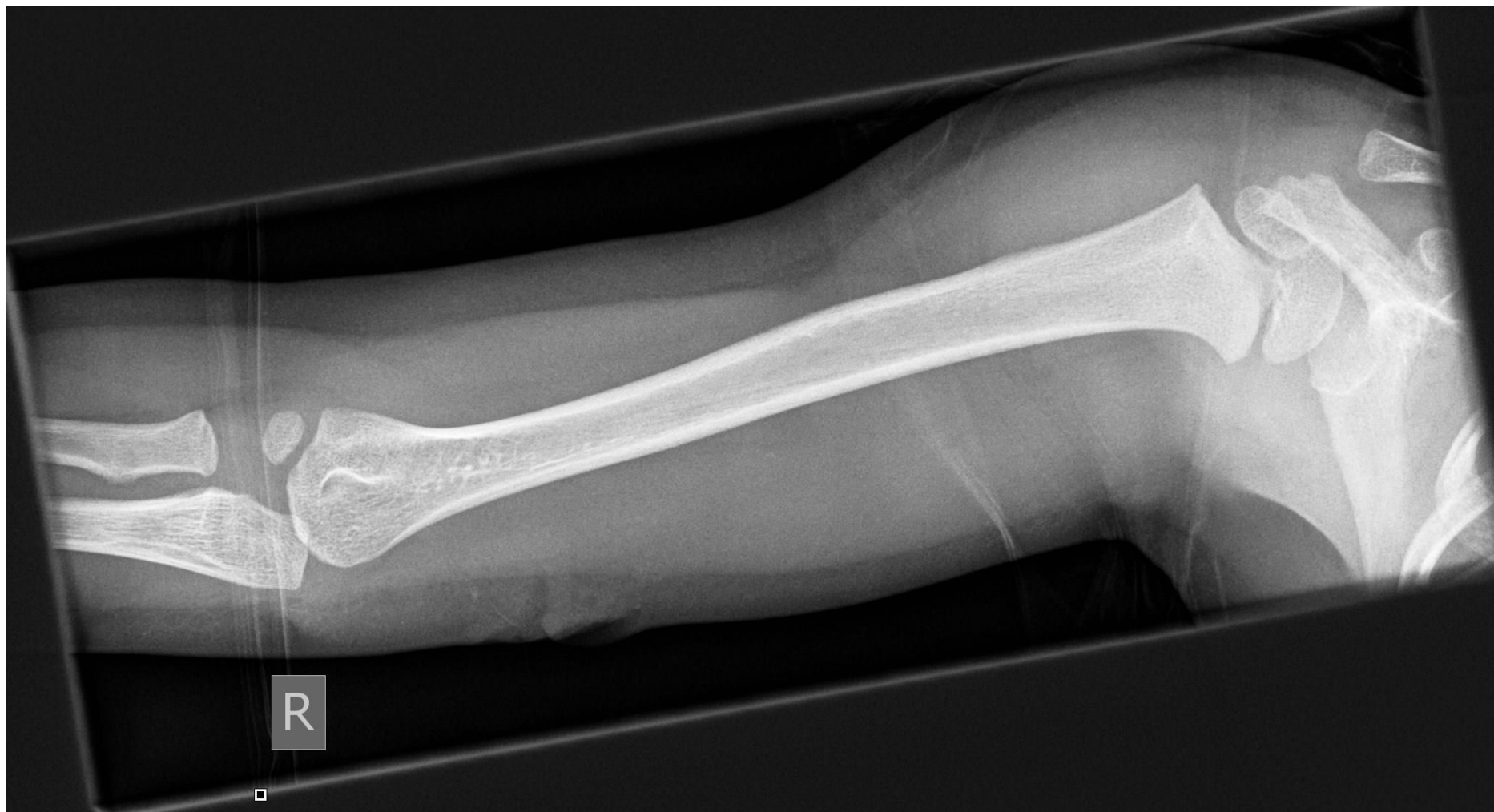# Normal Adult Elbow



# Upper Limb of 1 Year Old

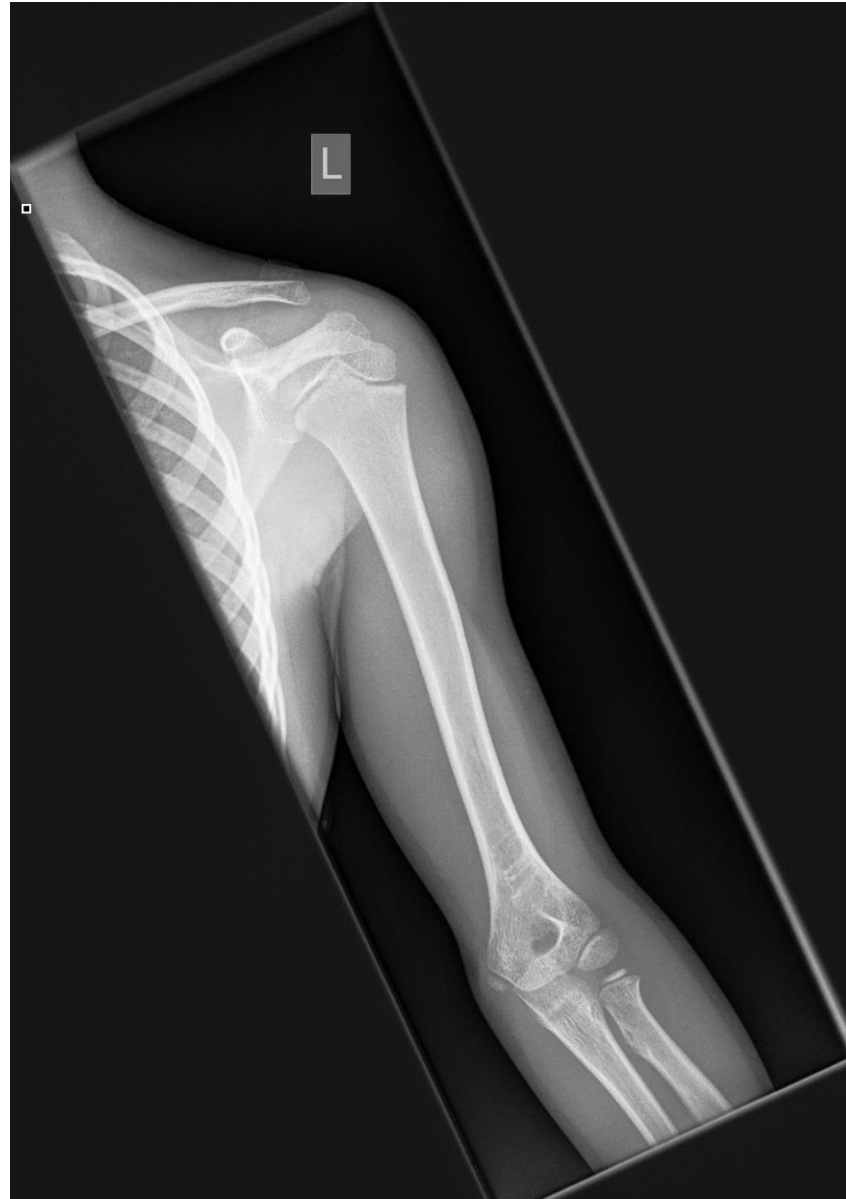

# Upper Limb of 4 Year Old

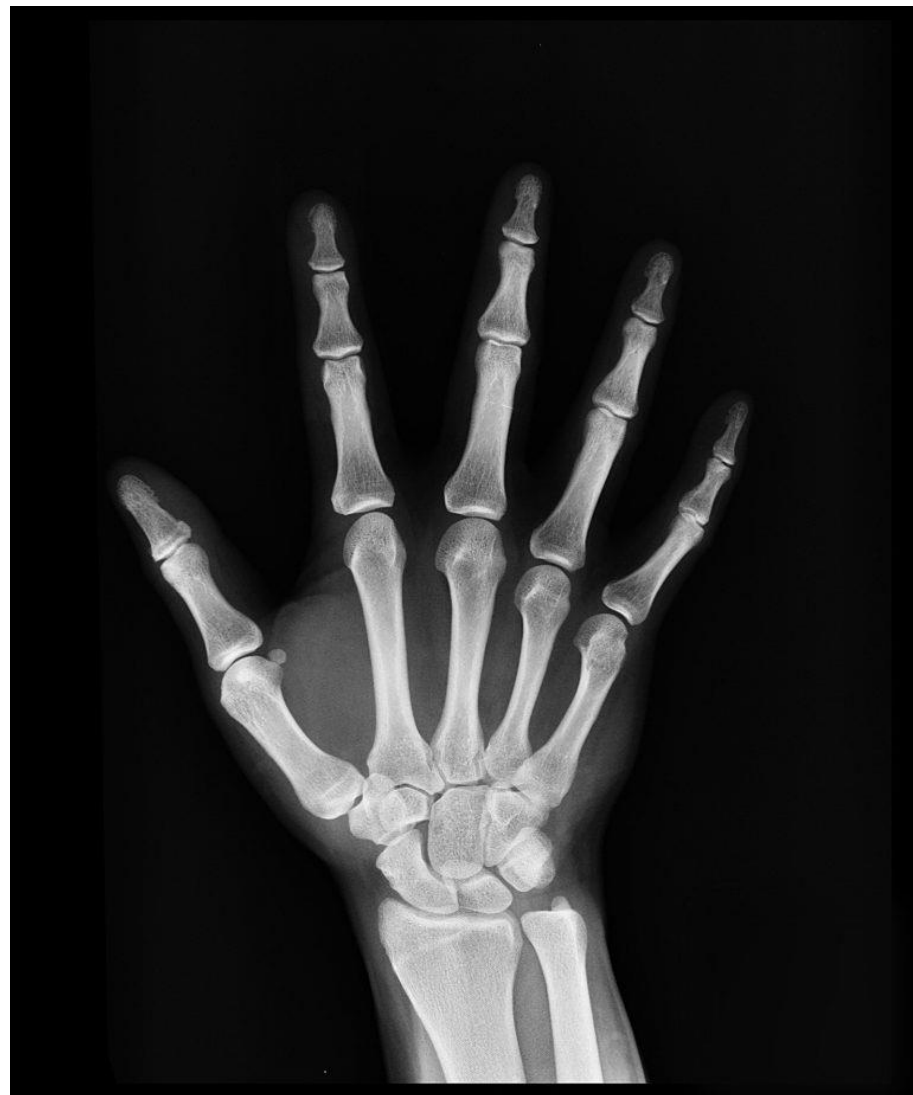



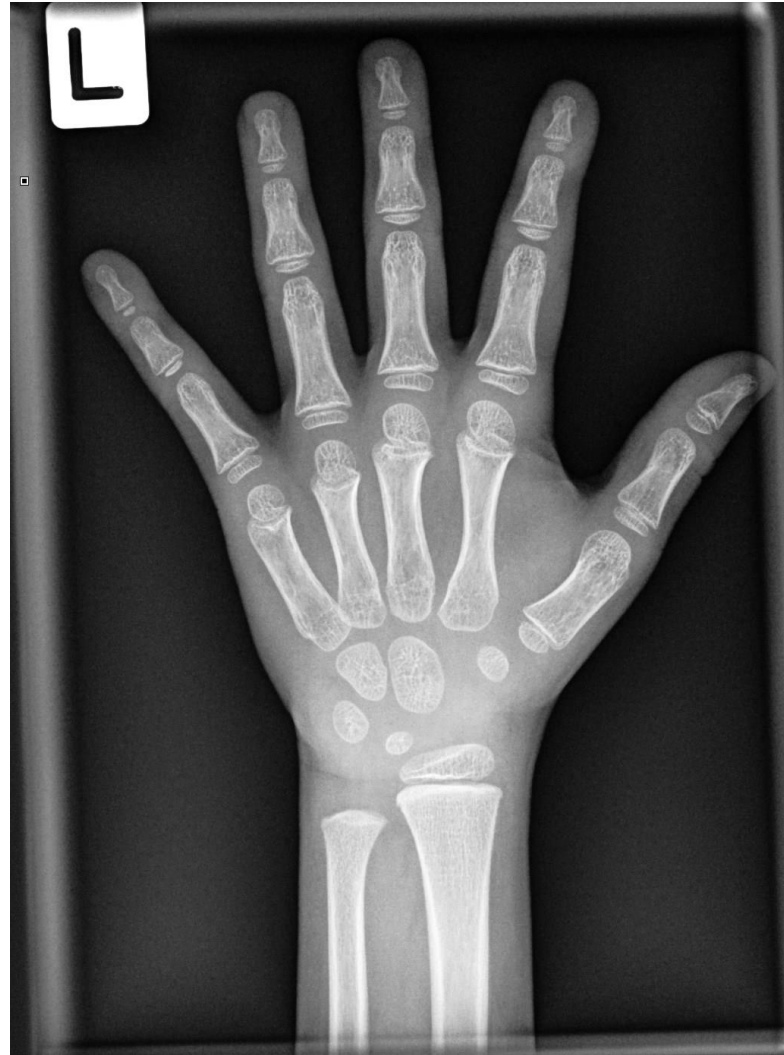# Upper Limb of 7 Year Old



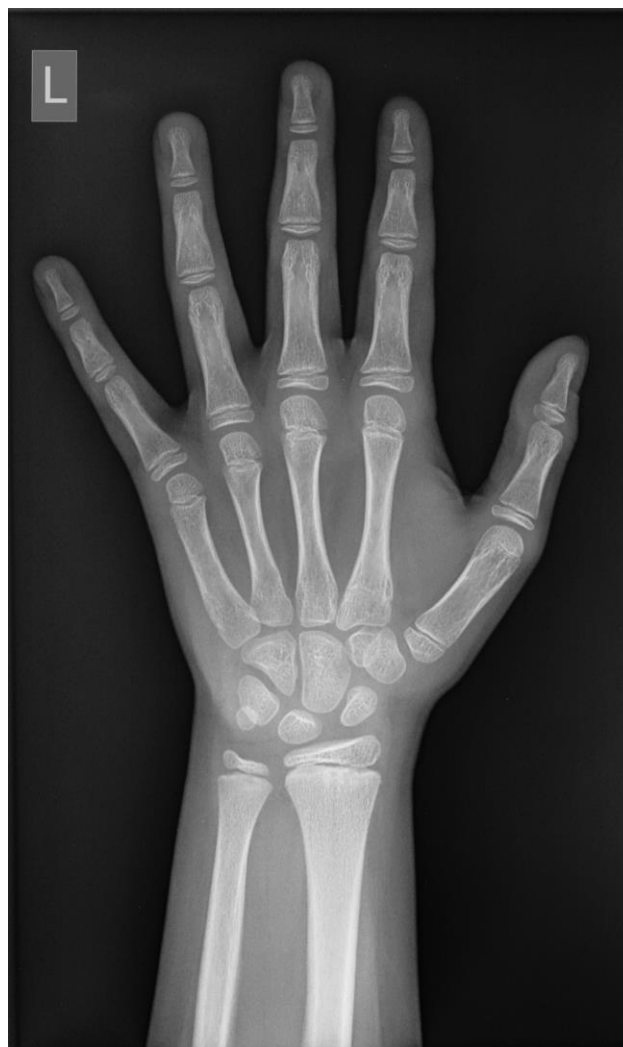# Normal Adult Hand



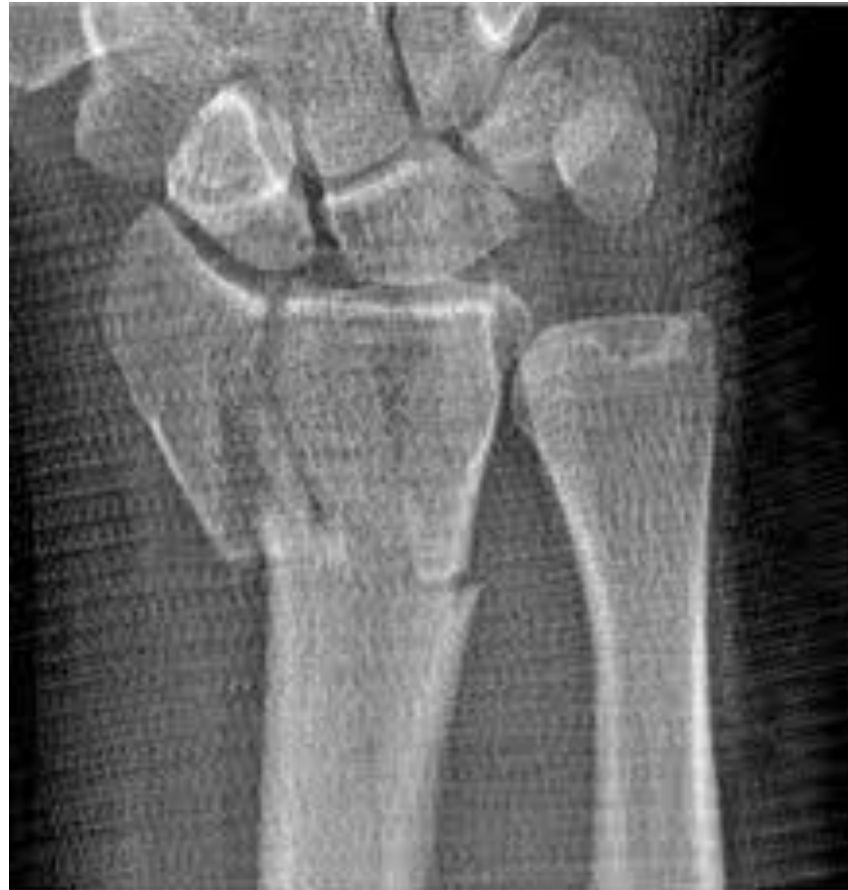# Normal Hand of a 5 Year Old



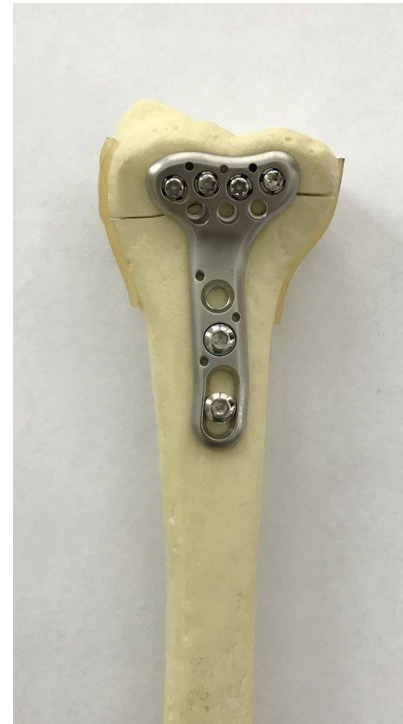
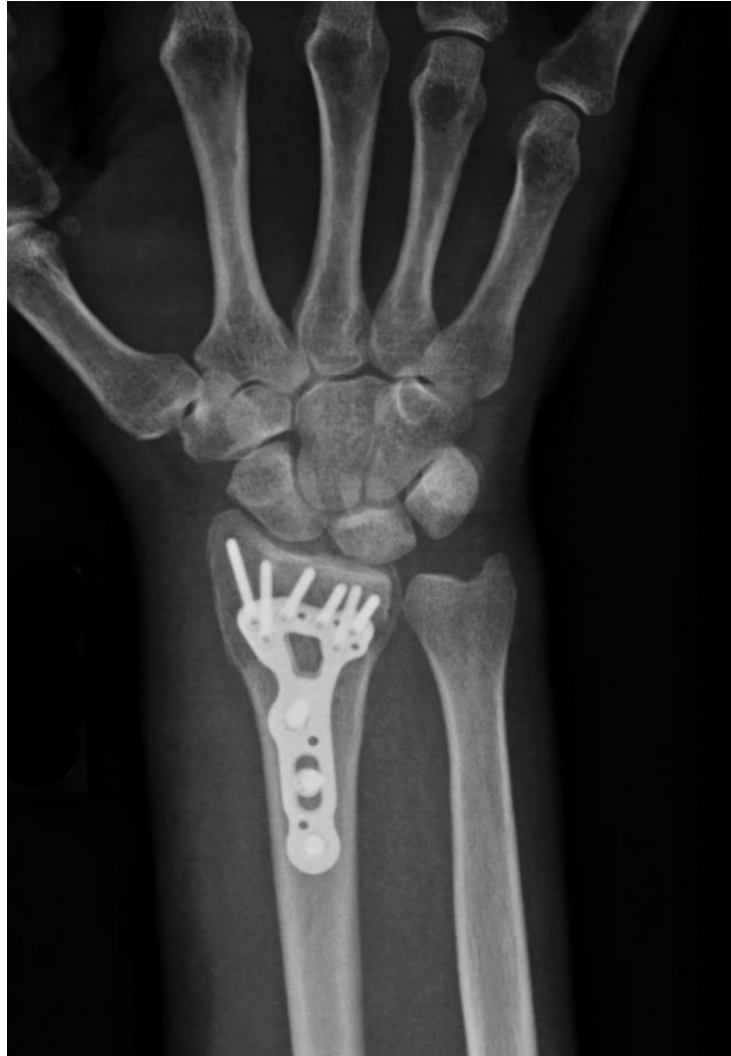# Normal Hand of a 10 Year Old



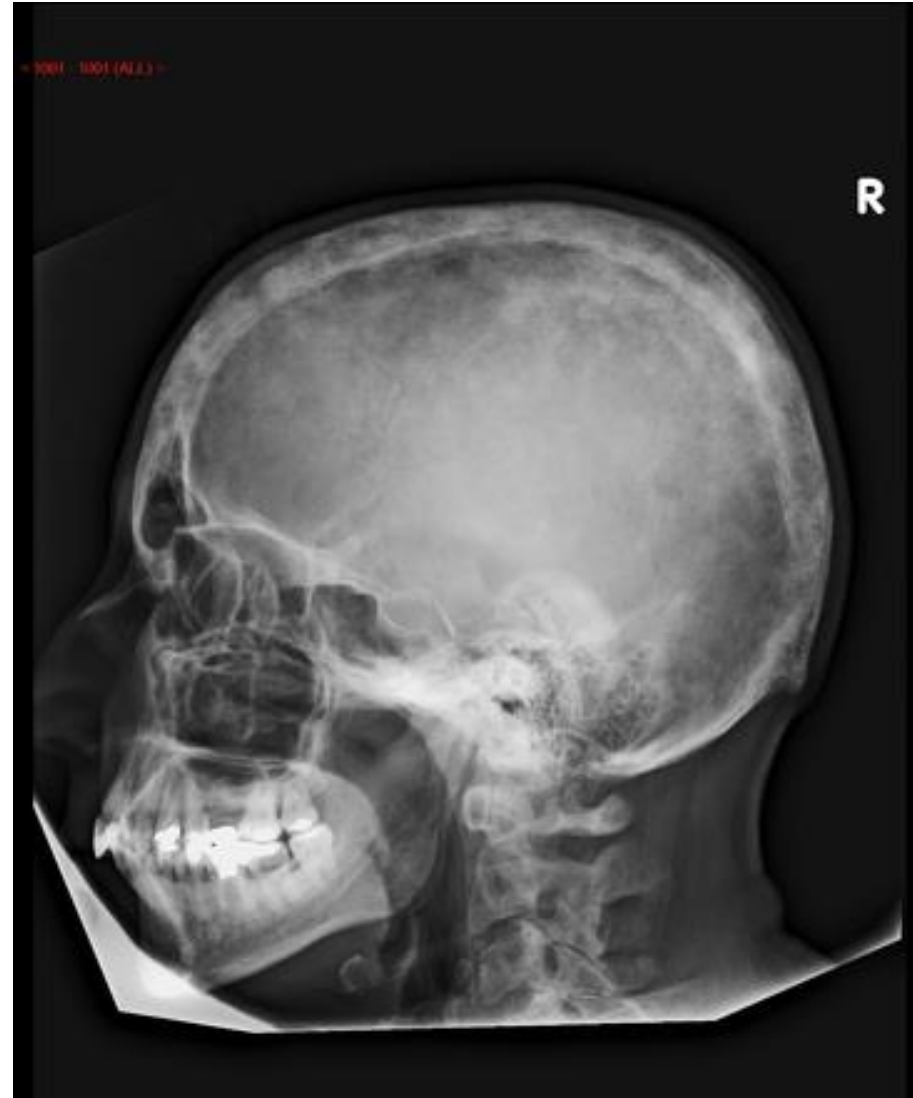# Broken Radius



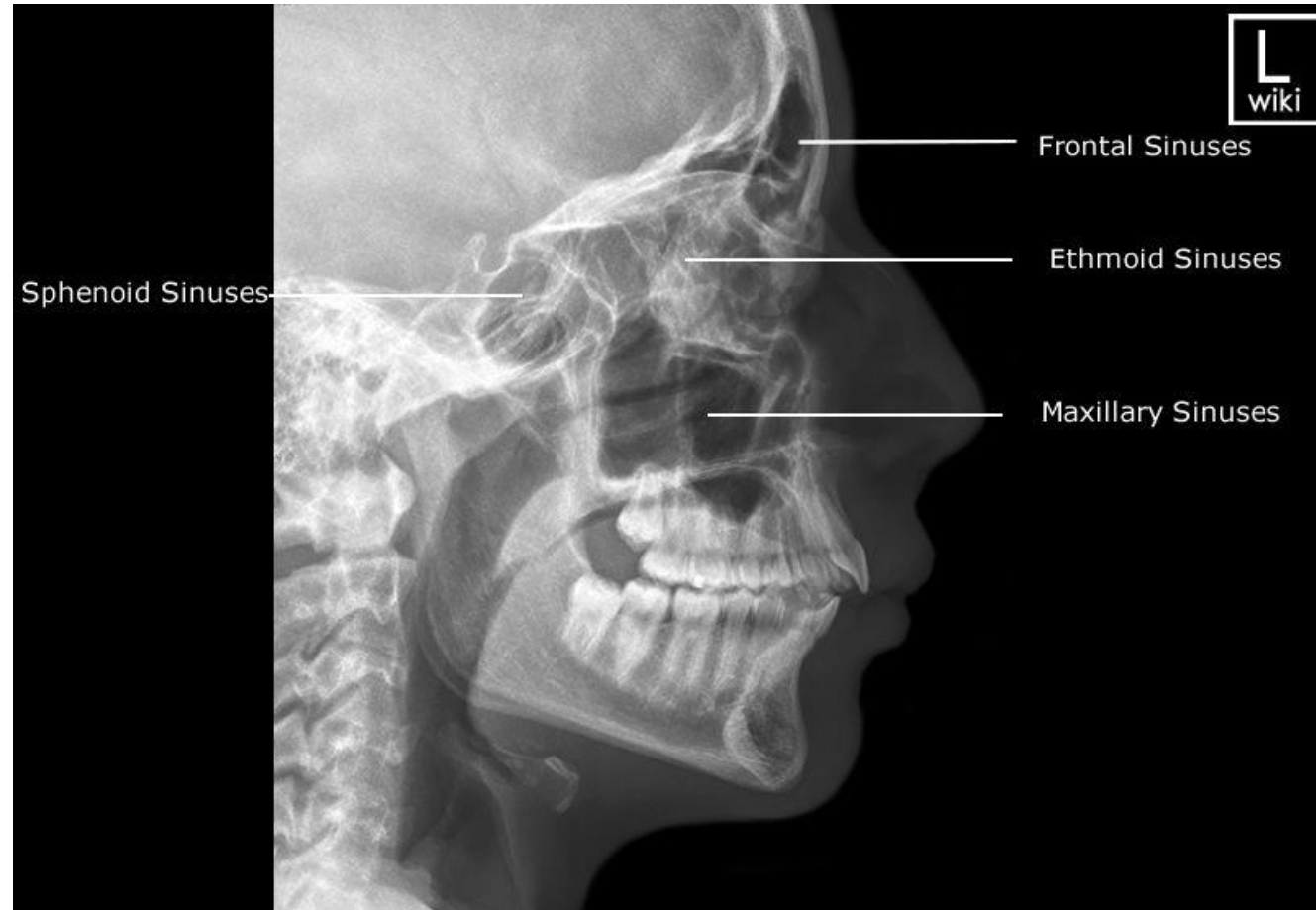
# Broken Radius Repair



# Normal Adult Skull

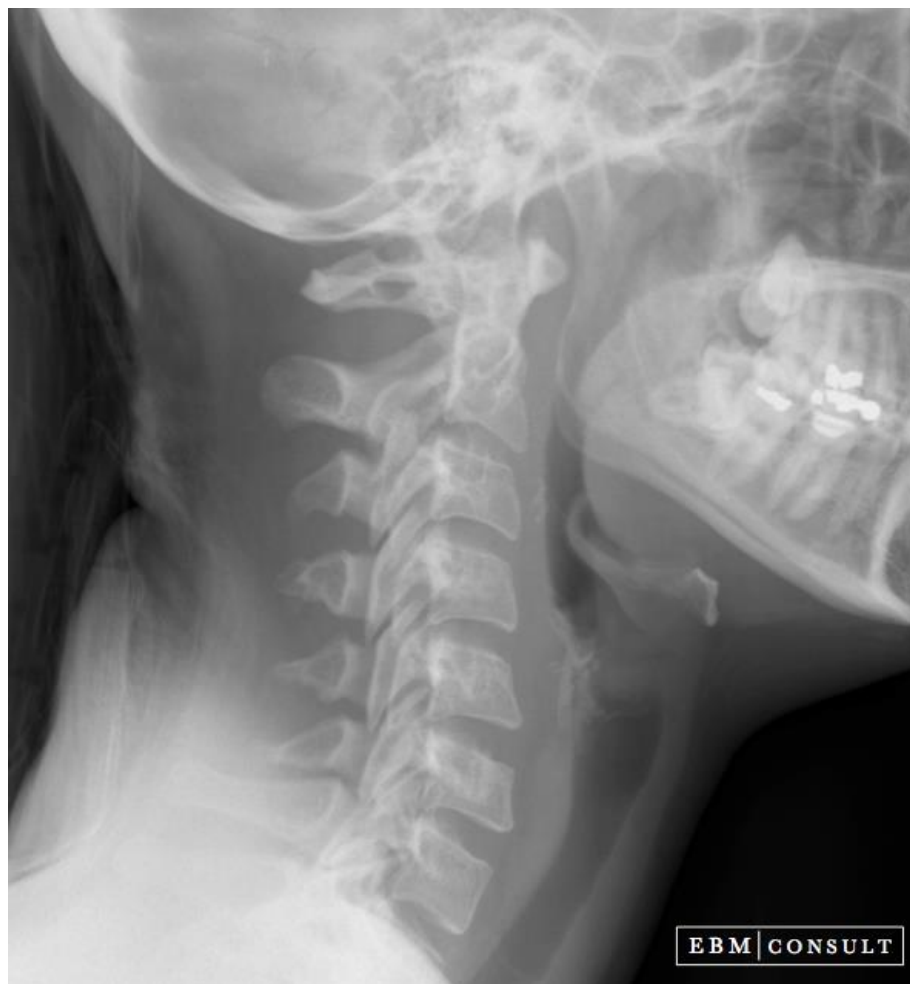

# Paranasal Sinuses

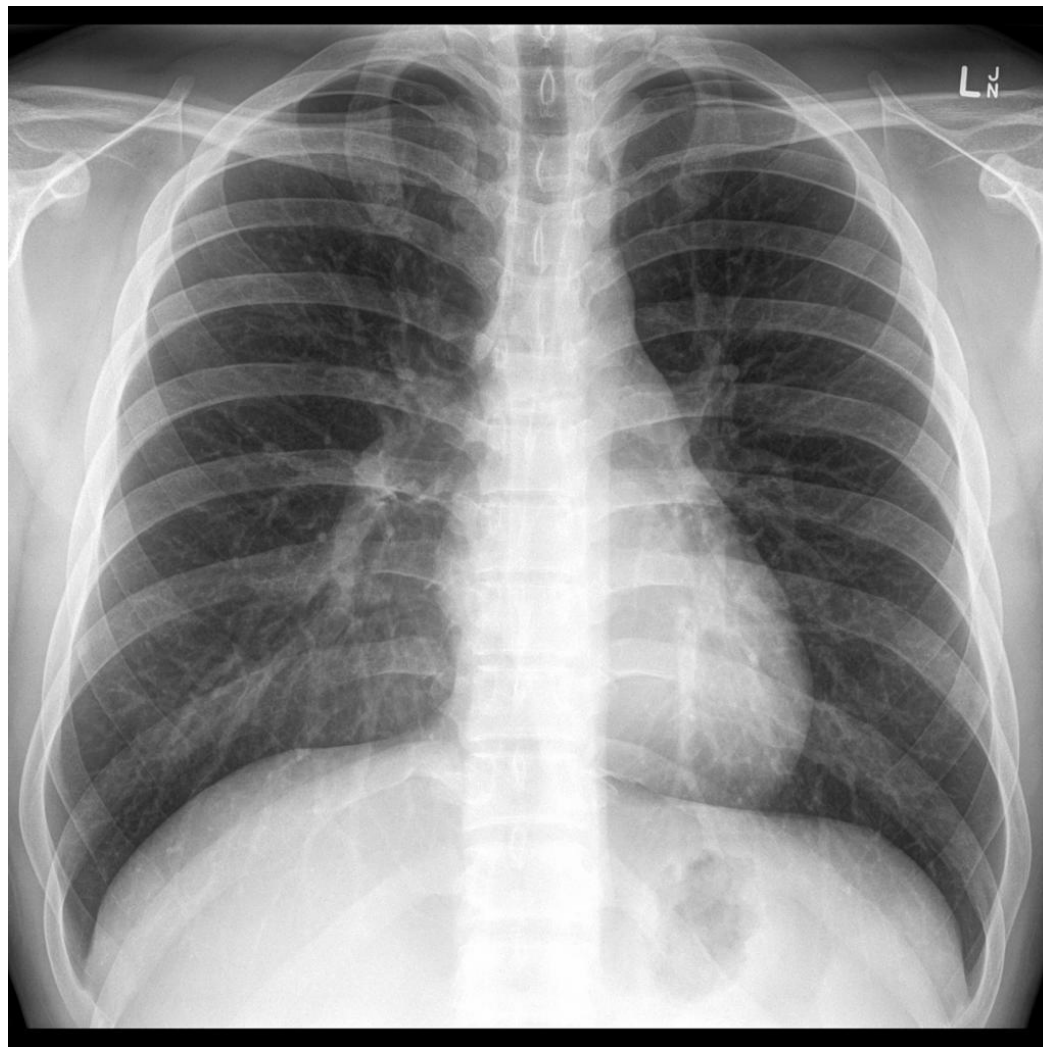




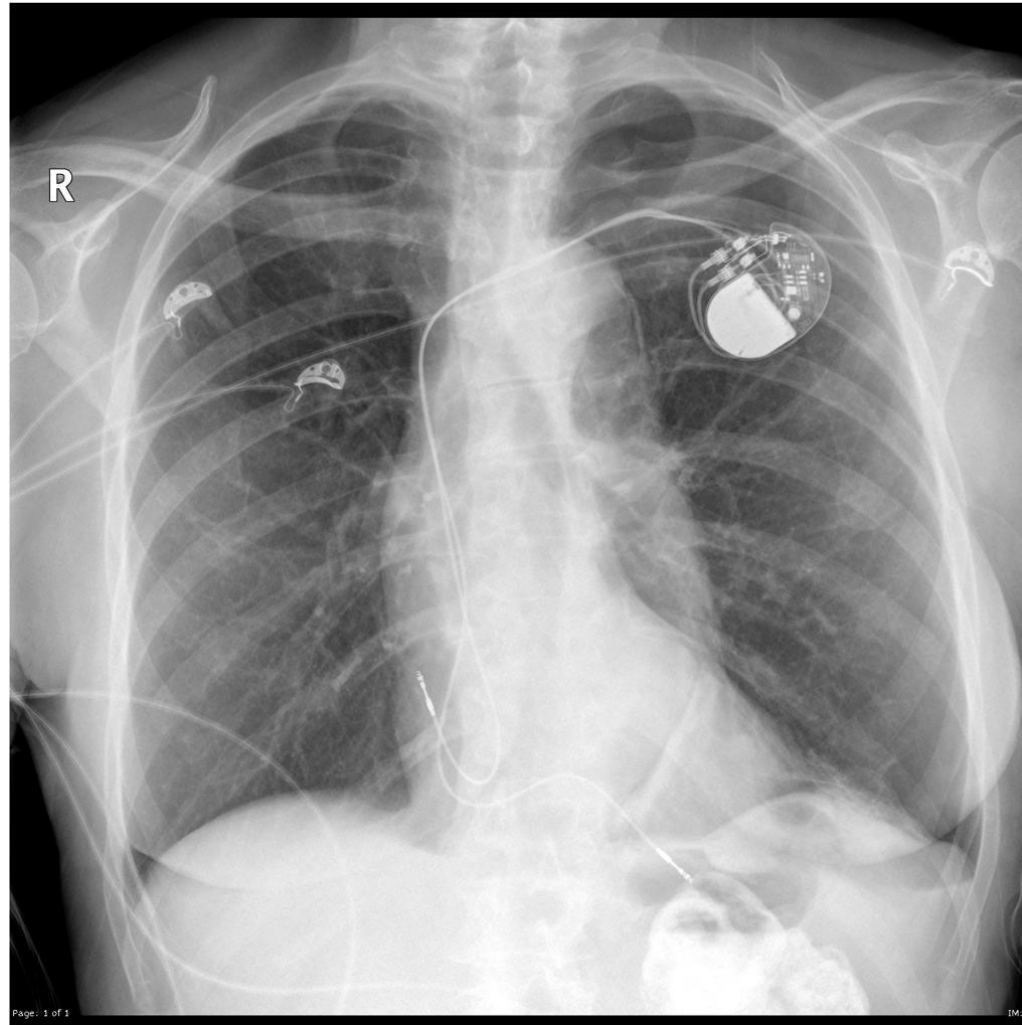
# Normal Cervical Vertebrae



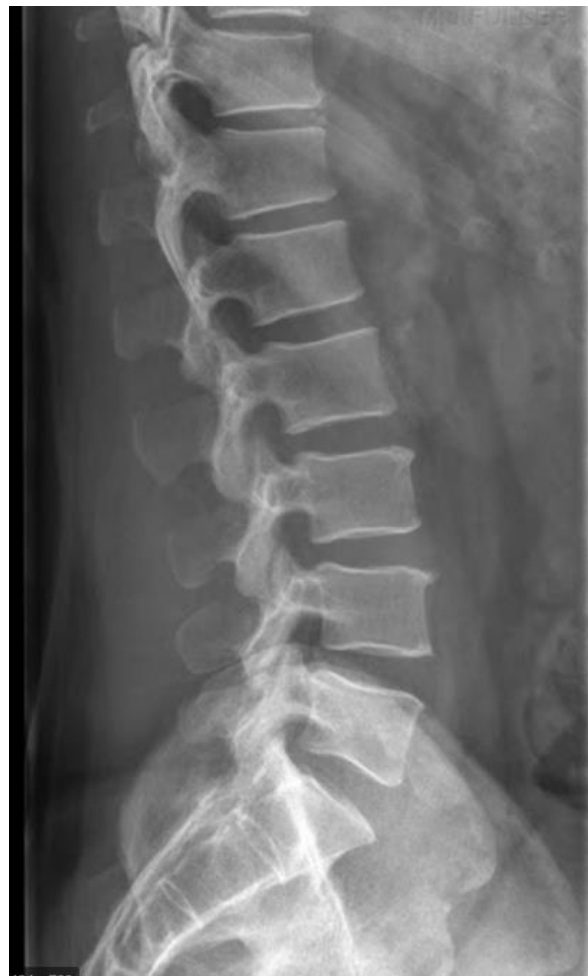# Normal Chest X-Ray



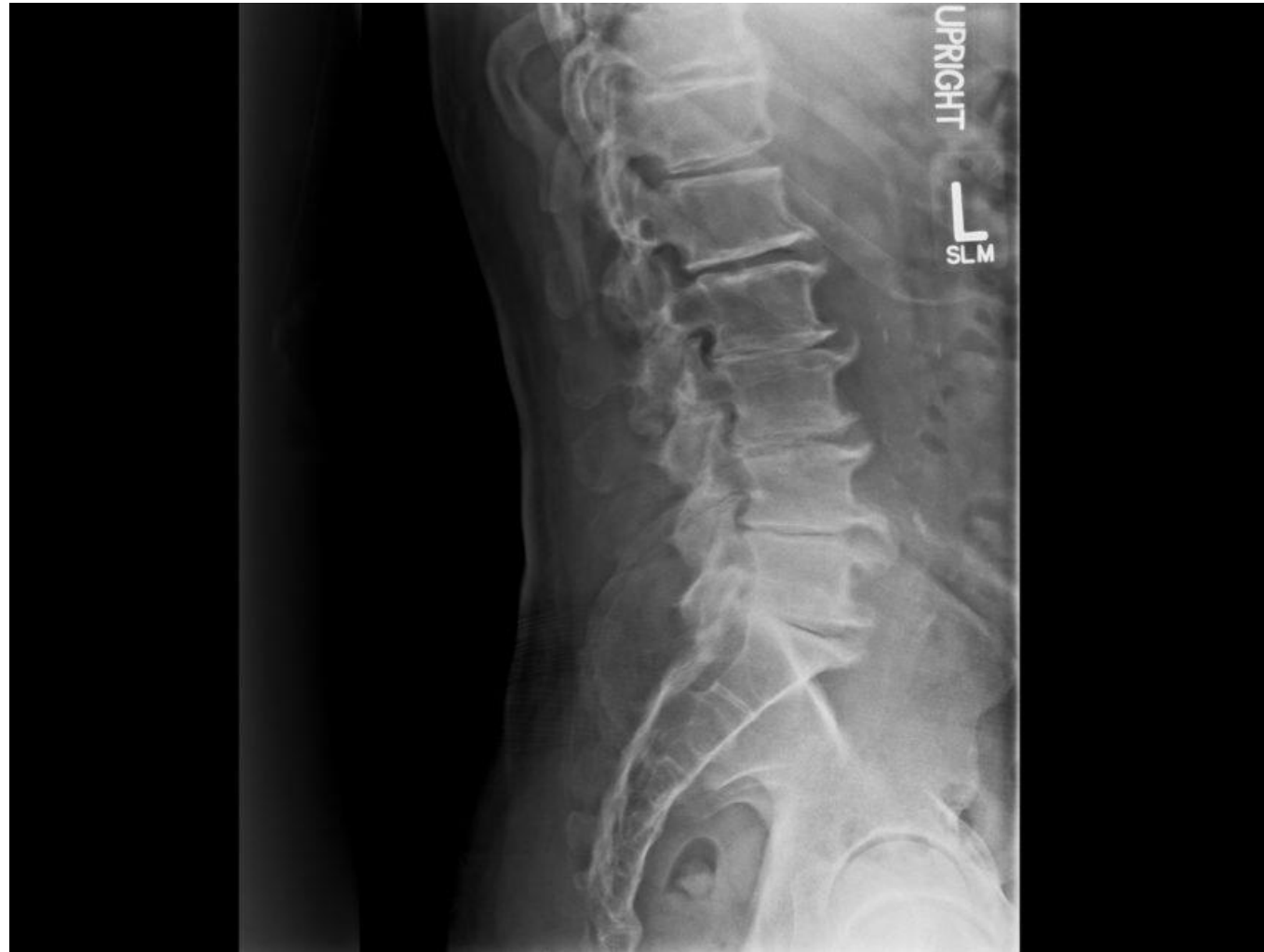# Chest X-Ray with Pacemaker



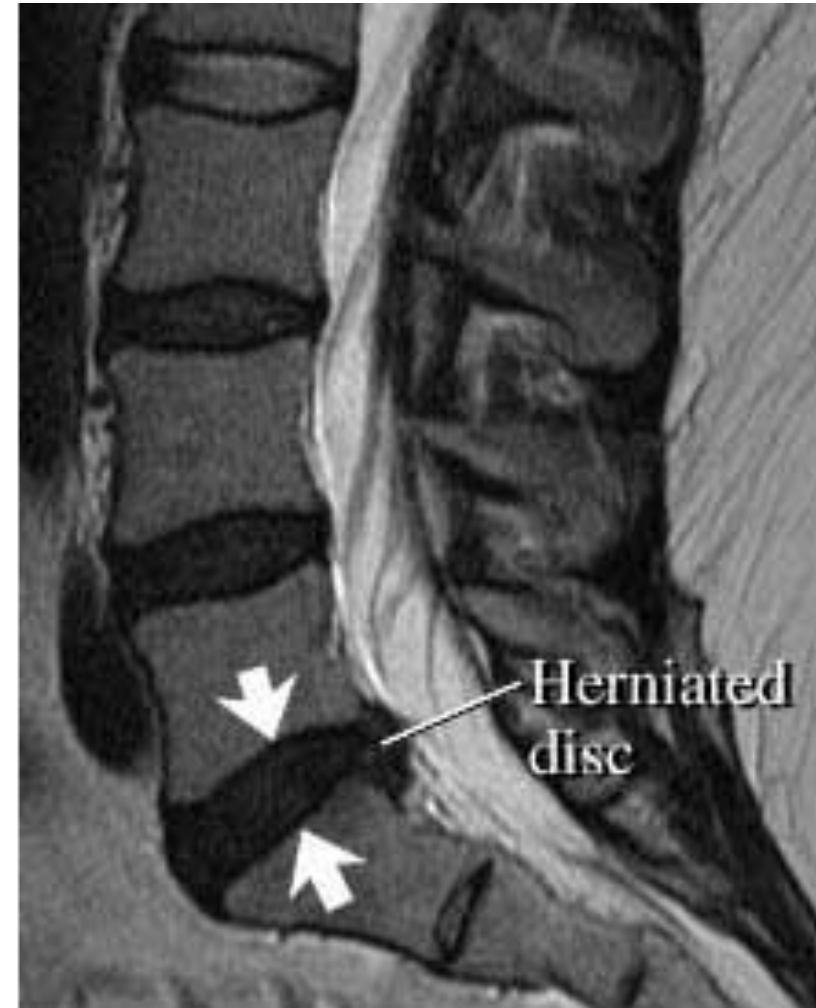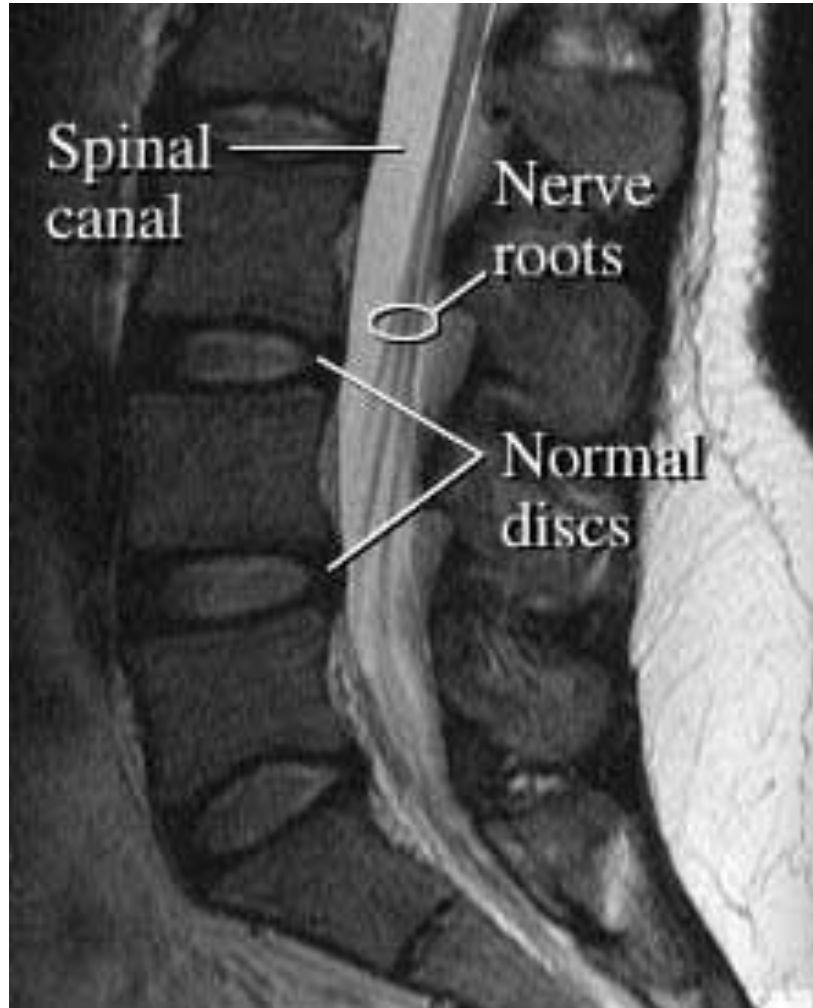
# Normal Lumbar Vertebrae



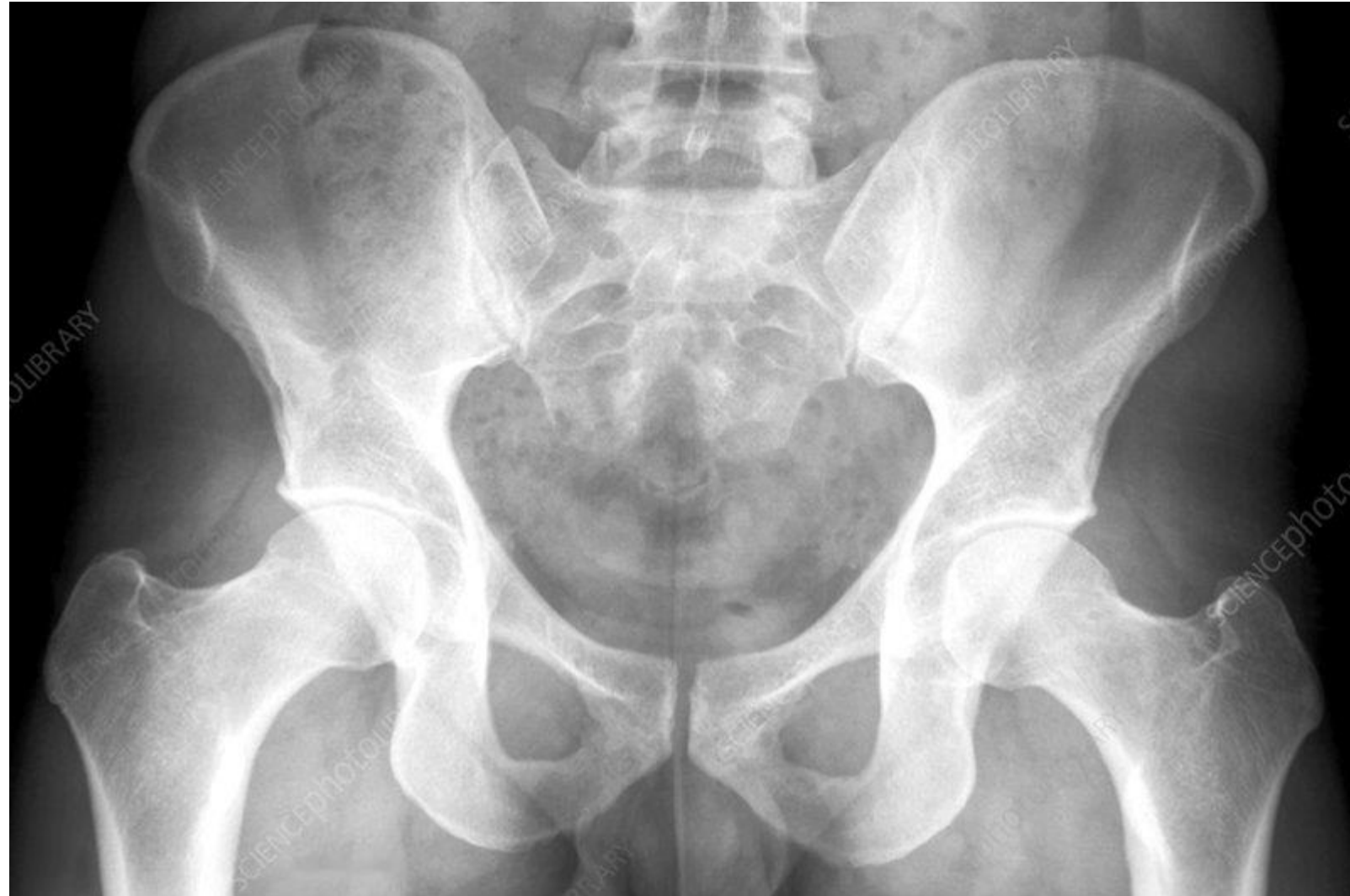# Degenerated Intervertebral Discs



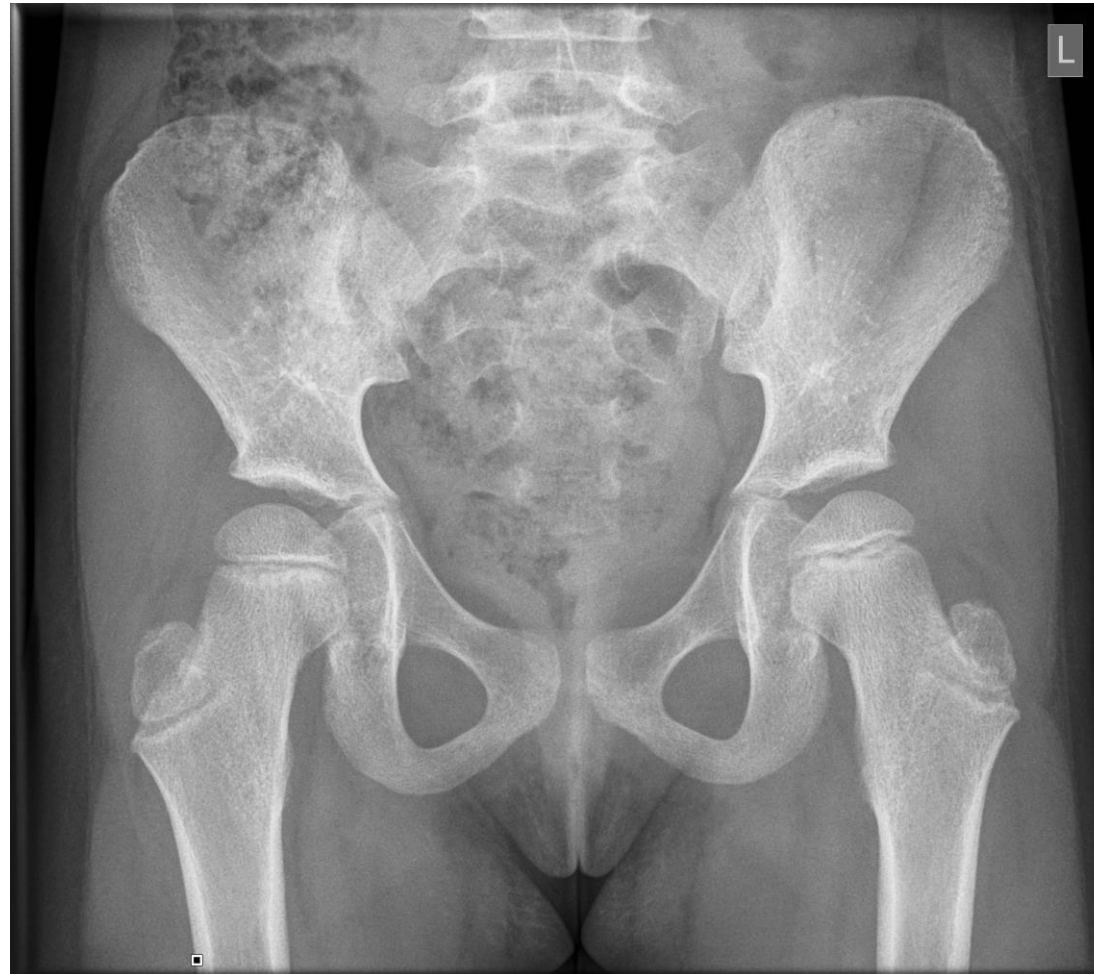## MRI of Normal and Herniated Discs



# Normal Adult Pelvis

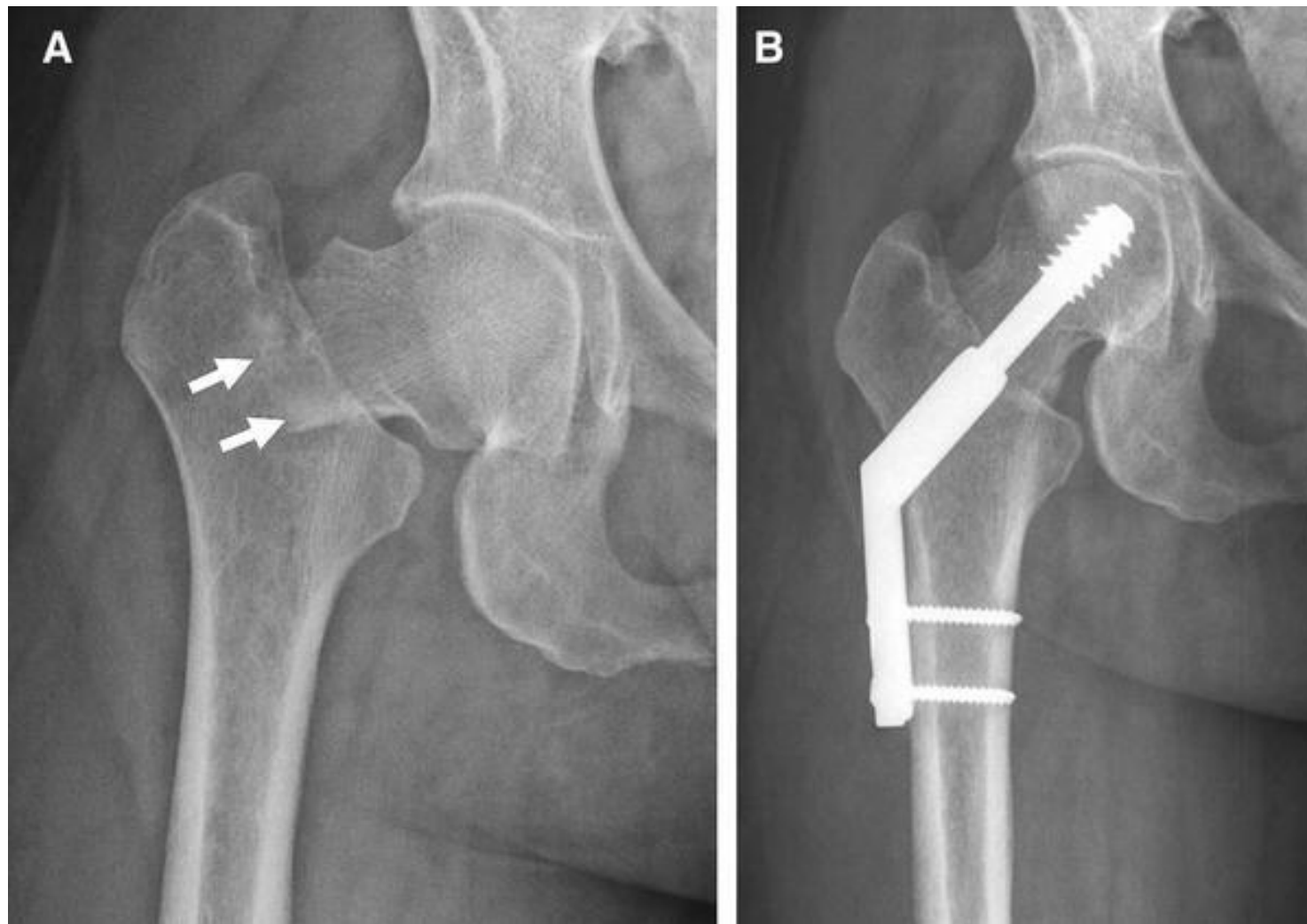


# Normal Pelvis of a 5 year old

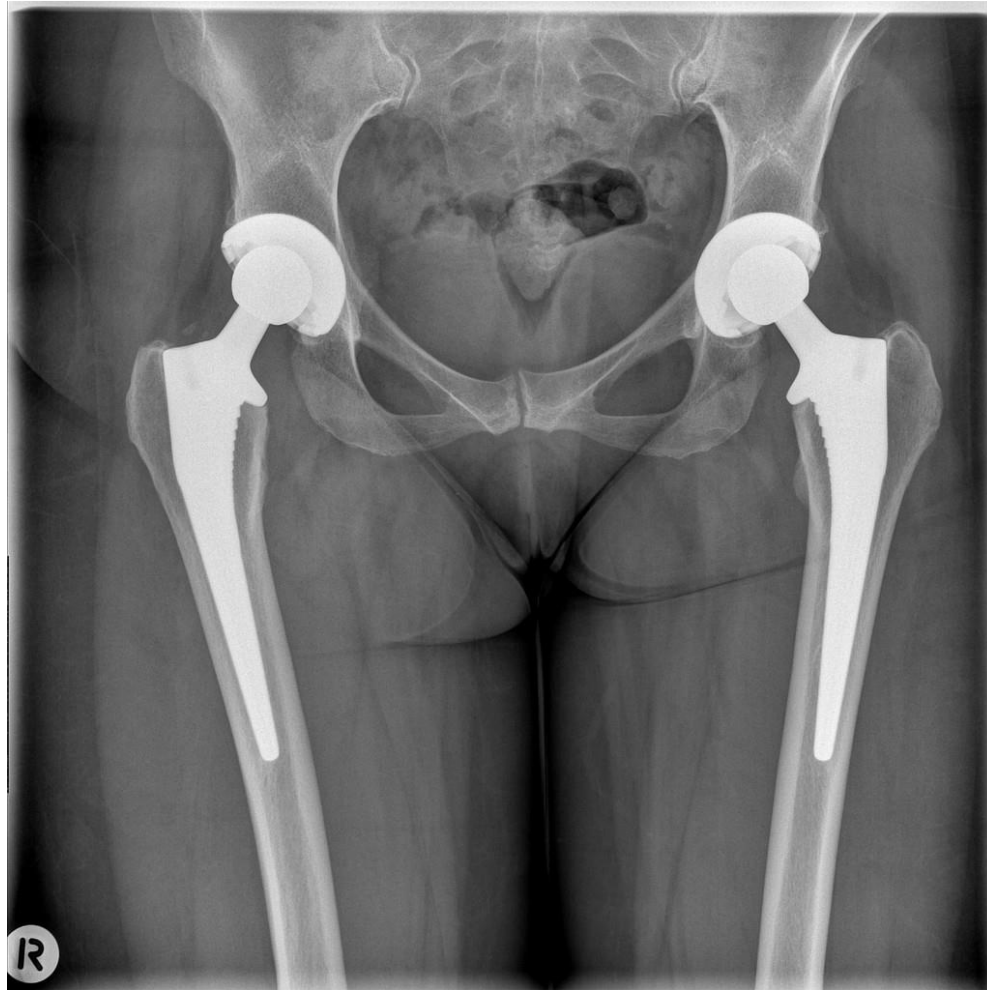



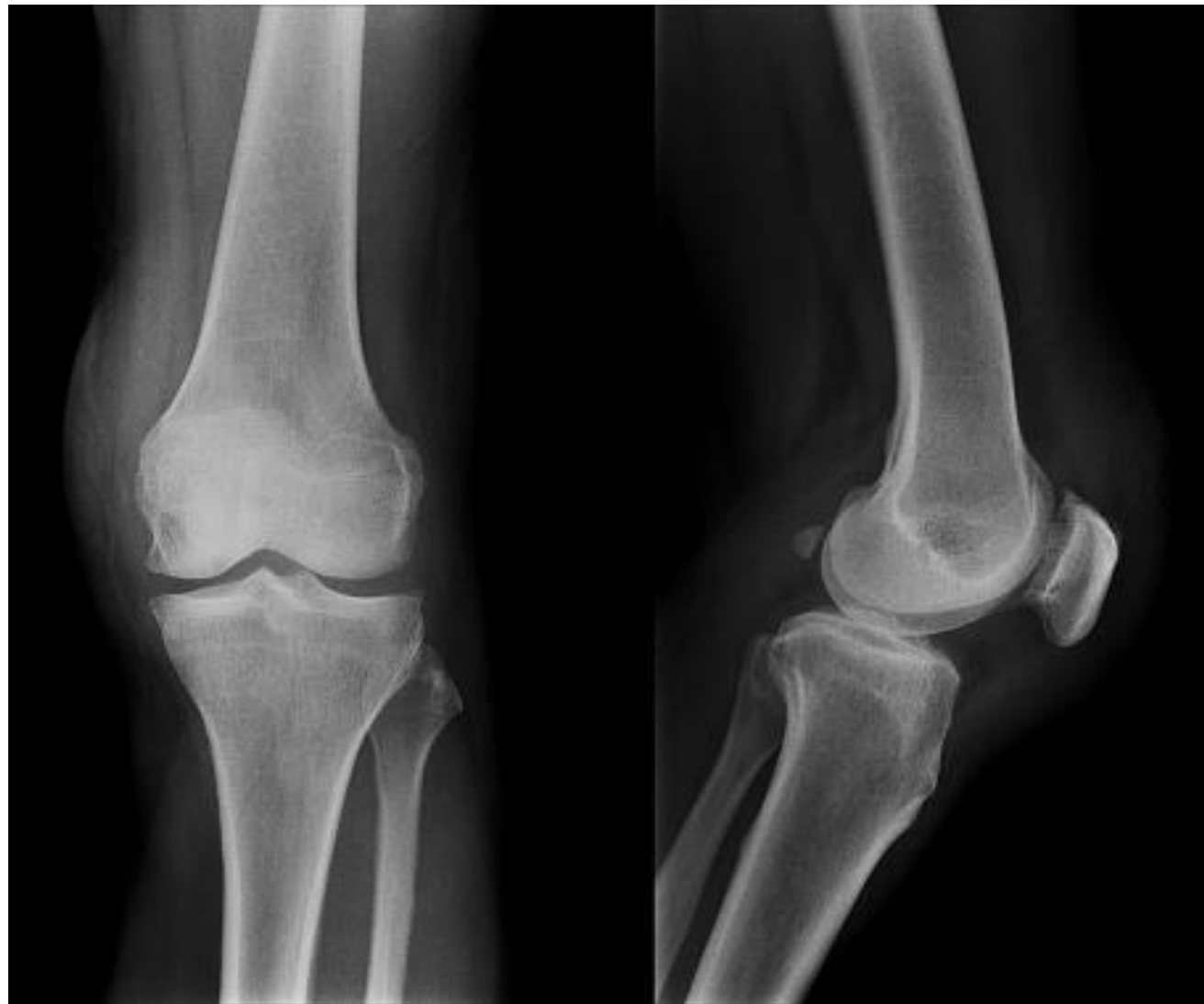## Broken “Hip” and Repair



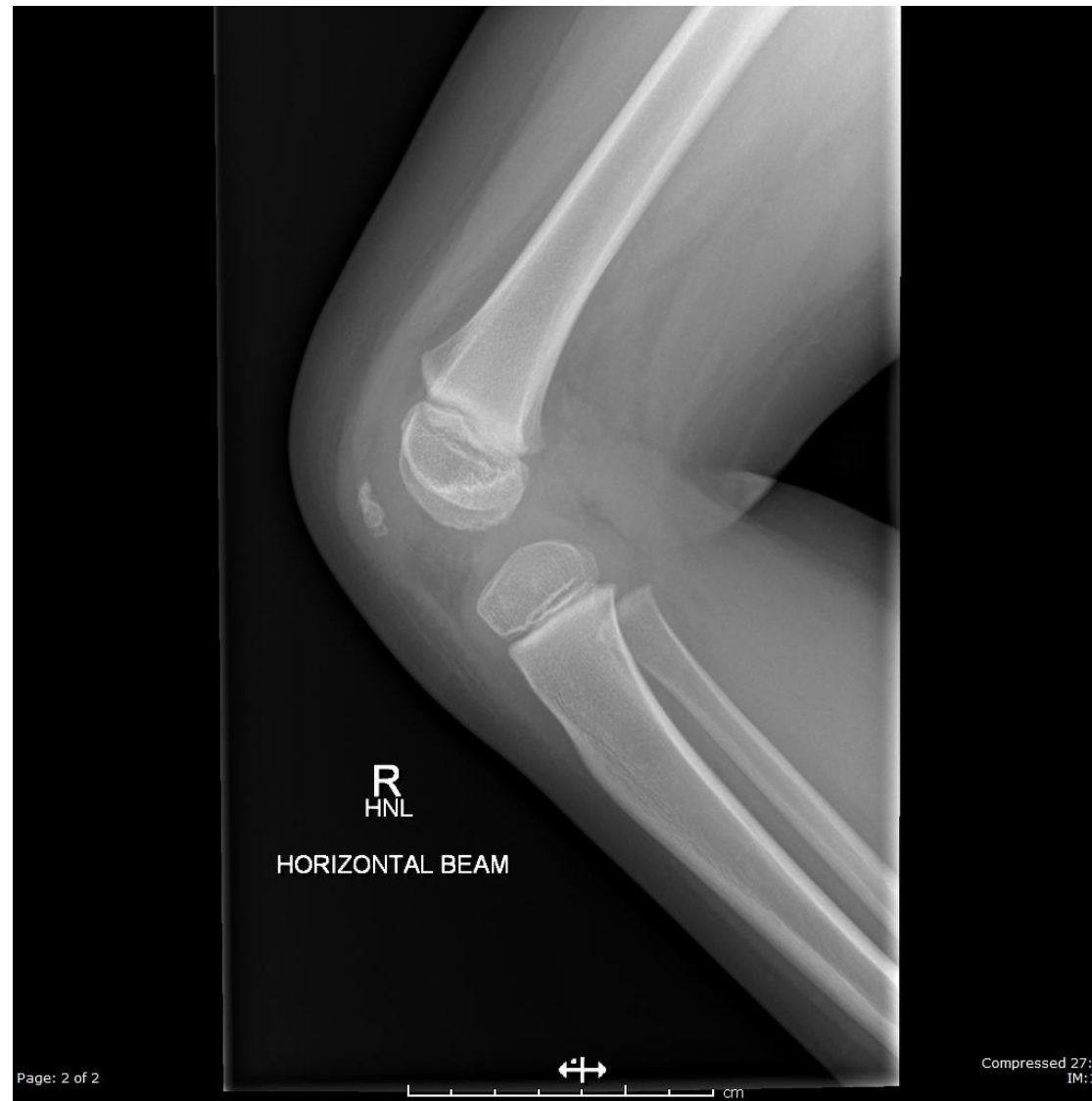# Hip Replacement



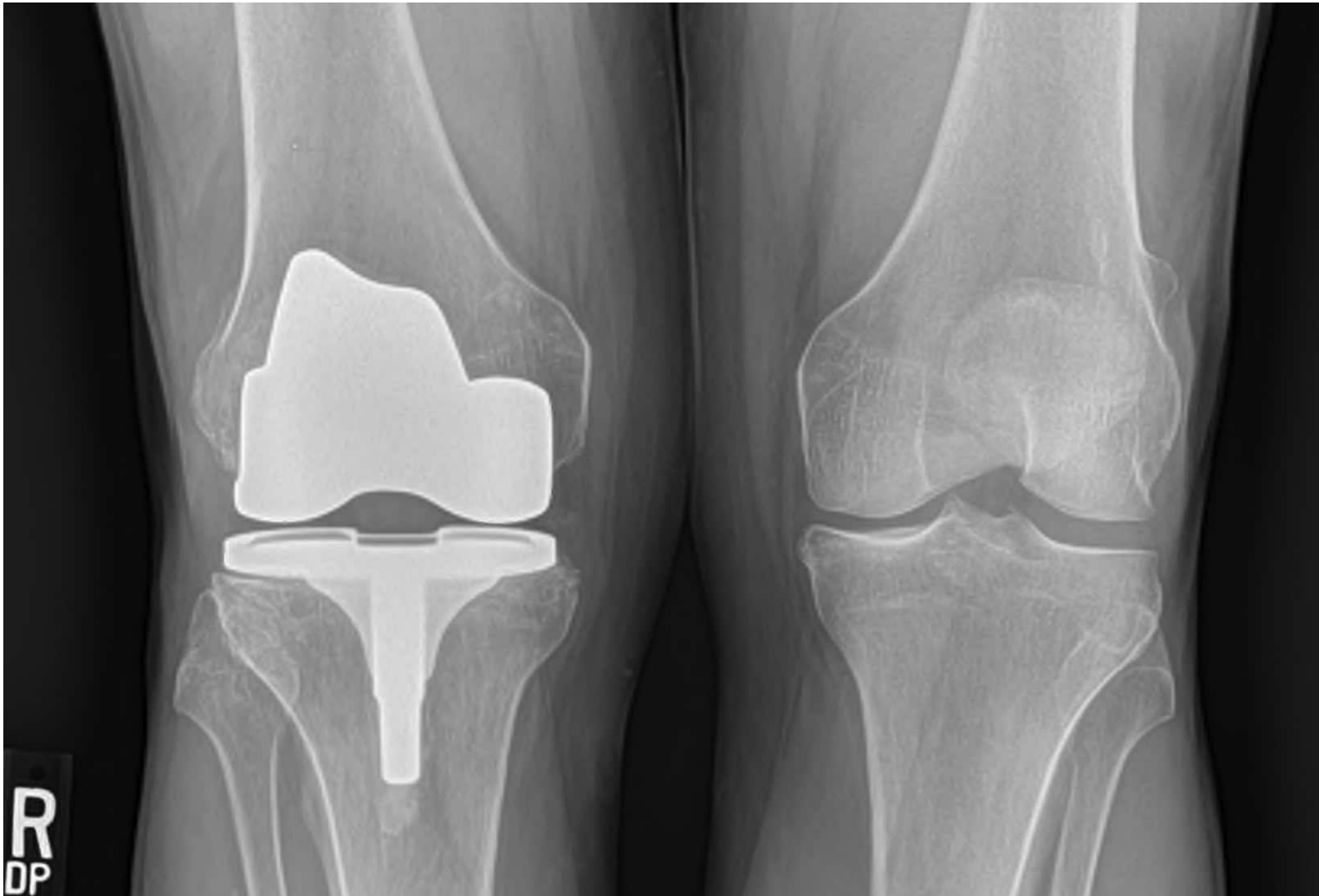
# Normal Adult Knee



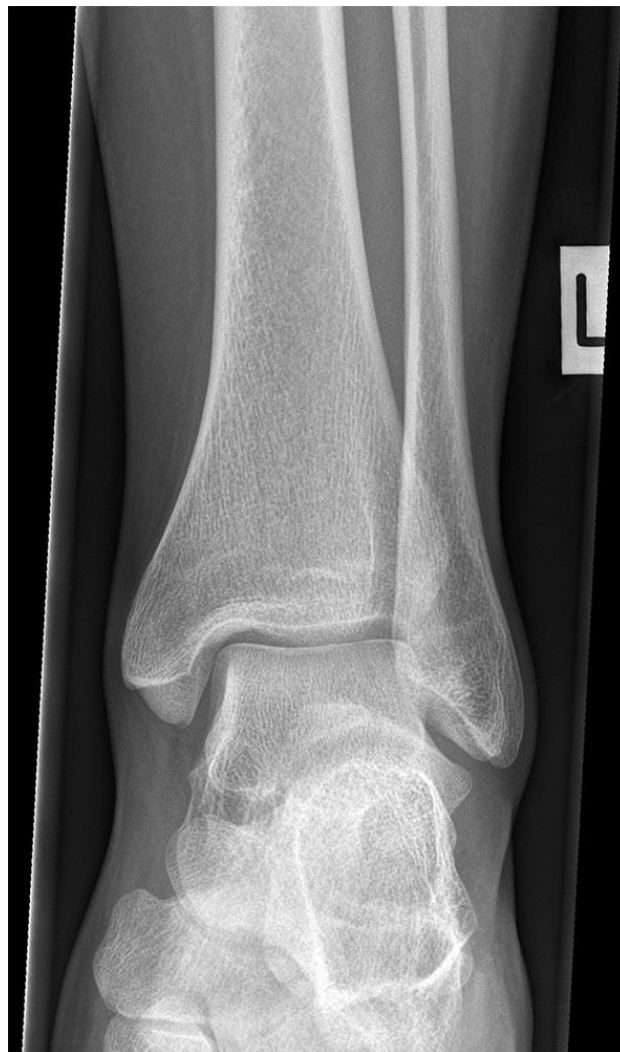# Knee of a 4 year old



# Knee Replacement

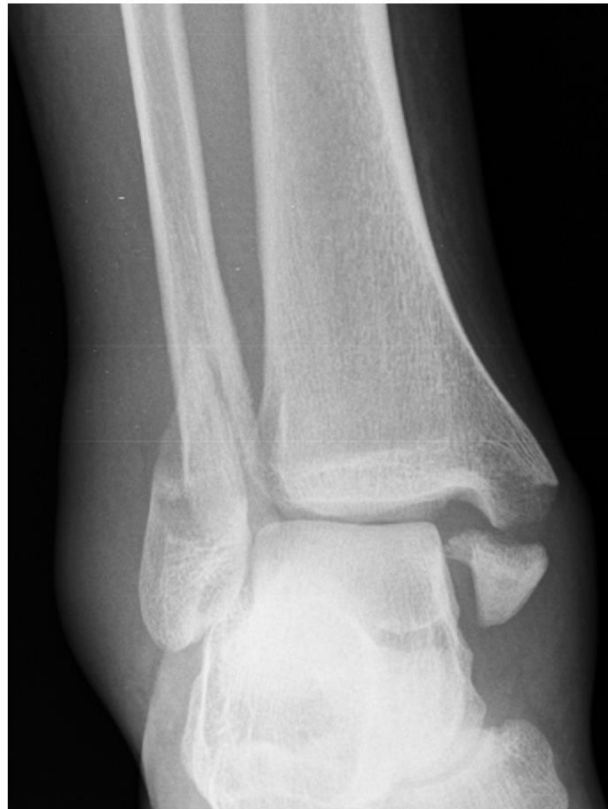

# Normal Adult Ankle

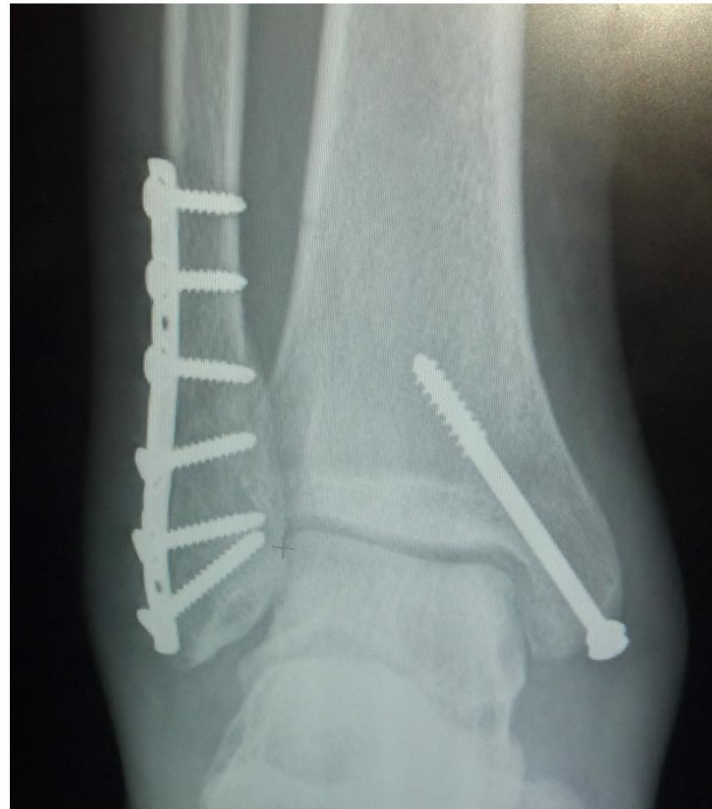

# Broken Ankle and Repair

**BEFORE**



**AFTER**



# Normal Adult Foot

